

Clinical Paper
Orthognathic Surgery

3D evaluation of postoperative swelling using two different cooling methods following orthognathic surgery: a randomised observer blind prospective pilot study

M. Rana¹, N.-C. Gellrich¹, U. Joos², J. Piffkó², W. Kater³

¹Department of Oral and Maxillofacial Surgery, Hannover Medical School, Carl-Neuberg-Str. 1, D-30625 Hannover, Germany;

²Department of Oral and Maxillofacial Surgery, University of Münster, Germany;

³Department of Oral and Maxillofacial Surgery, Hochtaunus University Teaching Hospital, Bad Homburg, Germany

M. Rana, N.-C. Gellrich, U. Joos, J. Piffkó, W. Kater: 3D evaluation of postoperative swelling using two different cooling methods following orthognathic surgery: a randomised observer blind prospective pilot study. *Int. J. Oral Maxillofac. Surg.* 2011; 40: 690–696. © 2011 International Association of Oral and Maxillofacial Surgeons. Published by Elsevier Ltd. All rights reserved.

Abstract. Orthognathic surgery is associated with side effects including severe postoperative swelling, pain, neurological dysfunction and trismus. The beneficial effects of localised cold treatment on postoperative swelling have been described. Topographical considerations make it difficult to quantify facial swelling. A new and promising method to measure facial swelling seems to be optical face scanning. This study aimed to evaluate the 3D optical scanner to measure soft tissue swelling following orthognathic surgery. Postoperative swelling was treated either with conventional cooling by cold packs or with the water-circulating cooling device Hilotherm Clinic. Secondary endpoints in each group included postoperative pain, neurological complaints, duration of hospital stay, trismus and patient satisfaction. The use of the cooling device by Hilotherm significantly reduced postoperative swelling, pain and hospital duration compared with conventional cooling. Postoperative trismus and satisfaction with the cooling method was significantly higher in the Hilotherm group compared with conventional cooling. No differences were observed concerning neurological score and outcome. In conclusion, 3D optical scanning is a simple and precise method of quantifying face swelling after orthognathic surgery. Hilotherm significantly reduces swelling and duration of hospital stay compared with conventional cooling.

Keywords: Orthognathic surgery; 3D optical scanner; Hilotherm; Swelling; Pain.

Accepted for publication 10 February 2011
Available online 15 March 2011

Orthognathic surgery is generally associated with side effects in the form of severe postoperative swelling, pain, facial oedema, inflammation and limited mouth opening due to muscle spasm (trismus)¹⁹. Postoperative pain is typically brief and

peaks in intensity in the early postoperative period, whilst swelling and trismus characteristically reach their maximum 48–72 h after surgery³. These side effects can be reduced by corticosteroids, non-steroidal anti-inflammatory drugs (NSAIDs), the combination of corticosteroids and NSAIDs and enzyme preparations such as serrapeptase^{3,8}. Methods such as manual lymph drainage, cryotherapy and soft laser seem to be alternatives^{16,20,22}. There is a lack of evidence to justify these methods so these forms of treatment are largely applied in an empirical manner.

The beneficial effects of localised cold treatment on postoperative swelling have been described extensively^{1,21}. The therapeutic use of cold is thought to have favourable effects on oedema, pain and inflammation^{1,21}. It also reduces bleeding and haematomas¹⁴. The pain relieving effects of cold are well documented and the activity of inflammatory enzymes is reduced in low temperatures. In the literature relating to oral and maxillofacial surgery there is little scientific evidence and few trials on the effects of cold application^{5,24}.

Topographical considerations make it difficult to quantify the facial volume of swelling. Various methods for measuring facial swelling have been proposed, such as verbal response scales, mechanical methods (cephalostat, callipers, registration of reference points or landmarks), ultrasound, photographic techniques, computed tomography (CT), and magnetic resonance imaging (MRI)^{3,13,17,20}. These techniques have shown variable accuracy and success and can be considered partial solutions. Some methods are described to predict soft tissue via cephalograms, which are able to create 3D images². Ethically, the benefit of cephalograms might not justify the patient's exposure to ionizing radiation. The most promising method of capturing the soft tissue of the human face seems to be optical face scanning with mirror construction. It precisely maps the entire face from ear to ear, over

180° with one capture, in a few seconds. The textures are photorealistic and provide digitalized data (lengths, surfaces, volume angles, symmetries).

This study aimed to evaluate the 3D optical scanner (3D-Shape GmbH, Erlangen, Germany) to measure soft tissue swelling in terms of volume (ml) following orthognathic surgery. Post-surgery swelling was treated with conventional cooling by cold packs or with the water-circulating cooling device Hilotherm Clinic (Hilotherm[®], Ludwigshafen, Germany). Secondary endpoints for each group included postoperative pain, neurological complaints, trismus (interincisal mouth opening) and patient satisfaction.

Materials and methods

Approval for the study was obtained from the relevant ethics committee at the University of Münster, Germany (CIS 2007-237-f-M). Positive written consent was obtained from each subject who participated in the study.

42 consecutive adult patients with an indication for orthognathic surgery were enrolled prospectively and observer blind. They were divided into two groups randomly. To reduce postoperative swelling, patients in the first group received conventional cooling therapy with cold packs, whilst patients in the second group were treated with a water-circulating mask with a continuous temperature of 15 °C by Hilotherm[®]. Exclusion criteria were syndromes such as cleft or craniofacial deformities. Patients with systemic or coagulative disorders, pregnancy and patients receiving any regular drug therapy (e.g. antiphlogistic), except for the oral contraceptive pill, were excluded from the study.

Surgical technique

The patients, all diagnosed with skeletal and dental malocclusion, had undergone preoperative orthodontic treatment. 42 patients were included in the study, 12

of 21 patients underwent a mandibular retrognathia in the conventional group and 14 of 21 in the Hilotherm group (Table 1). Accordingly, 9 of 21 patients underwent a mandibular prognathism in the conventional group and 7 of 21 in the Hilotherm group. The surgical procedure was a standardised Le Fort 1 maxillary downfracture technique as described by EPKER⁷ and mandibular surgery described by OBWEGESER¹⁸. Intermaxillary fixation was carried out for 24 h. The surgery was performed by a single surgeon. Drug therapy in both groups included 1000 mg paracetamol (Perfalgan[®]) intravenously and 100 mg diclofenac (Voltaren[®]) per day for 3 days from the second postoperative day as anti-inflammatory and analgesic therapy. Antibiotic prophylaxis consisted of ceftriaxone 2000 mg/day for 4 days. Perioperatively a single dose of 50 mg steroids (Solu Decortin[®]) was administered to each patient.

Study intervention

21 patients were assigned to conventional cooling and 21 patients to the water-circulating external cooling device Hilotherm Clinic. The order of the cooling method was determined randomly and was not influenced by the clinicians responsible for the individual patients. For both groups, cooling was initiated as soon as possible after surgery until postoperative day 3 continuously for 16 h daily.

Conventional cooling consists of using cold packs. Cool packs were changed every 2 h. The water-circulating cooling system consists of a thermoplastic polyurethane mask connected to the Hilotherm device (Fig. 1A). Figure 1B and C demonstrates how the mask covers the face during the cooling procedure. The temperature setting is adjustable from +10 to +30 °C and was set to +15 °C. It is possible to choose between short-time mode, interval mode and continuous. In short-time mode, the device performs for the preset period of time and shuts off after completion. In interval operation, the system continuously performs according to the preset operating and pause intervals. For continuous duty the system works continuously.

3D optical scanner

The FaceScan3D optical 3D sensor (3D-Shape GmbH, Erlangen, Germany) consists of an optical range sensor, two digital cameras, a mirror construction and a commercial personal computer (Fig. 2). It was used to measure the amount of swelling by

Table 1. Baseline characteristics of patients.

	Hilotherm [®]	Conventional	<i>p</i> value
Gender female no./total no. (%)	17/21 (67)	14/21 (78)	0.304
Age (years)	25.1 ± 1.5	28.7 ± 2.3	0.208
BMI (kg/m ²)	24.0 ± 1.0	23.9 ± 0.9	0.945
Operation duration (min)	154.3 ± 5.8	153.6 ± 5.5	0.929
Hospitalization duration (days)	6.3 ± 0.1	6.7 ± 0.1	0.05
Mandibular retrognathia no./total no. (%)	14/21 (67)	12/21 (57)	0.537
Mandibular prognathism no./total no. (%)	7/21 (33)	9/21 (43)	0.537
Maxillary movement (mm)	3.1 ± 0.3	3.3 ± 0.3	0.629
Mandibular movement (mm)	5.9 ± 0.5	5.5 ± 0.6	0.674

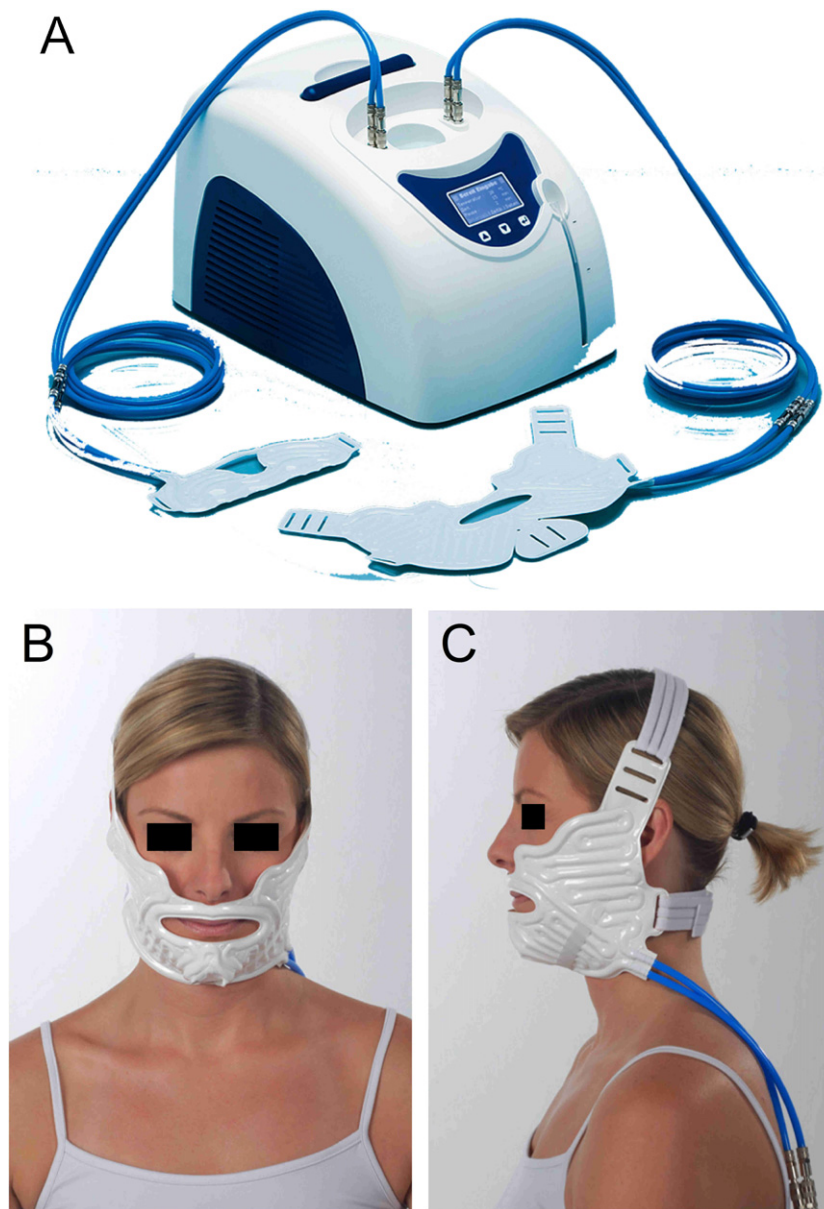


Fig. 1. (A) The Hilotherm[®] device connected with two masks. A maximum of two masks can be connected to one Hilotherm[®] device. The temperature can be adjusted from 10 to 30 °C. The display demonstrates the current degree of water circulating through the mask and the temperature set by the operator. (B) Front view and (C) side view of a patient wearing the mask.

volume (ml). The sensor is based on a phase-measuring triangulation method⁹. The advantage of this optical sensor is contactless data acquisition along with high accuracy in the z-direction with 200 μm and a short measurement time of 640 ms. There is no need for special safety precautions to protect the patient from, for example ionizing radiation. The light intensity of the cameras is low. A special mirror construction that allows the patient's face to be captured from ear to ear in a single recording from over 180° was designed. Slim3D (3D-Shape, Erlangen, Germany), a computer program,

automatically triangulates, merges and post-processes the 3D data¹⁵. The final 3D output is a triangulated polygon mesh, visualized as a synthetically shaded or wire-mesh representation¹². 3D optical scans were recorded over five time periods: T0 (preoperative scan), T1 (day 2 postoperatively), T2 (day 3 postoperatively), T3 (day 4 postoperatively) and T4 (6 months postoperatively) (Fig. 3). For each patient, time point T4 was chosen as the reference, because at this time point swelling of soft tissue could be excluded, which could influence the measurements. Annotations of T0–T4 were prepared by

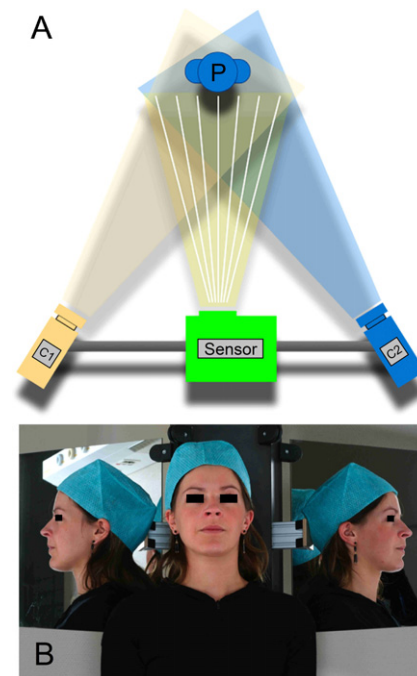


Fig. 2. (A) The setup of the 3D optical scanner by 3D-Shape GmbH (Erlangen, Germany). P = patient, C1 = camera 1, C2 = camera 2. (B) The special mirror construction that allows an image of the patient's face to be captured from ear to ear in a single recording from over 180°. Slim3D software (3D-Shape, Erlangen, Germany) automatically triangulates, merges and post-processes the 3D data.

an error minimization algorithm by modified Iterative Closest Point (ICP) using simulated annealing and Levenberg–Marquardt¹⁵. To minimize the disturbance of soft tissue during the registration process only regions of the faces that were not influenced by the swellings were used for surface matching: forehead, ears and root of the nose. The geometric models were aligned with the forehead and the ears. The aligned shell deviation panels were created for cut off to create an individual mask of the middle face. Finally, the difference in volume was calculated.

Postoperative pain analysis

Pain analysis was performed using a visual analogue scale (VAS) as described previously²³. Briefly, pain was graded on a score from 0 to 10, where as 0 denotes no pain and 10 maximum intensity of pain.

Postoperative neurological score analysis

Neurological analysis was done for infra-orbital and mental nerve bilaterally as described previously⁶ with some modifi-




Fig. 3. The final 3D output of the Slim3D software is a triangulated polygon mesh, visualized as a synthetically shaded representation. 3D optical scans were recorded during five time points: T0 (preoperative scan, image not shown), T1 (day 2 postoperatively), T2 (day 3 postoperatively), T3 (day 4 postoperatively) and T4 (6 months postoperatively). The reference 3D model of each patient was T4. An individual mask of the midface of each patient was created and aligned to all captures and the difference in volume was calculated.

cations. This method was created for nerve reconstructions. The authors used this neurological score to evaluate nerve dysfunction after orthognathic surgery. Briefly, the skin of the infraorbital region and the upper lip was checked using a cotton test for touch sensation, a pinprick test using a needle for sharp pain and a blunt instrument for pressure. In addition, a two point discrimination test was performed on these regions. The same observation was carried out on the lower lip and the mental nerve skin region. The results were graded with a score ranging from 0 to 13, where 13 was the worst neurological score. The scores were collected on day 4 and 6 months postoperatively.

Analysis of mouth opening (trismus)

Trismus was calculated with interincisal mouth opening and was measured with a calliper. The results were quoted in millimetres and were observed at four time points: pre-operative, day 2, day 4, and after 6 months.

Patient satisfaction of cooling therapy

All patients were given a questionnaire before discharge from hospital. They were asked to report their subjective perception of the comfort and satisfaction of the postoperative cooling therapy. The data were graded on a scale of 1–4, where 1 was very satisfied and 4 not satisfied.

Statistical analysis

All data are expressed as mean values \pm 1 SEM. A one-way analysis of variance (ANOVA) with post hoc Bonferroni's test for multiple comparisons of means was used for repeated measures. Student's *t*-test was applied for quantitative variables. A *p* value $<$ 0.05 was considered significant. Statistical analysis was carried out with SPSS software for windows Version 14.0 (SPSS Inc., Chicago, IL, USA).

Results

42 patients were enrolled in the study. After orthognathic surgery, 21 patients

were assigned to conventional cooling and 21 patients to the water-circulating external cooling device. The clinical and demographic characteristics are given in Table 1. No differences were found with respect to gender, age, body mass index, operation duration and surgical technique (Table 1). Significantly shorter hospitalization duration was found in the Hilotherm group compared with the conventional group (6.3 ± 0.1 days versus 6.7 ± 0.1 days, respectively, $p = 0.05$).

Postoperative swelling

Swelling was measured in terms of volume in millilitres. Figure 3 demonstrates representative 3D optical scans of a patient at different time points. By postoperative day 2 a significant down-regulation of swelling was achieved by cooling with Hilotherm compared with conventional cooling (92.9 ± 7.0 ml versus 120.2 ± 8.8 ml, respectively, $p = 0.03$) (Fig. 4). This trend was maintained during postoperative days 3 and 4. On day 3 the Hilotherm value was 87.1 ± 7.2 ml compared with the conventional value of 124.1 ± 10.1 ml ($p = 0.01$). On day 4 the Hilotherm value was 72.5 ± 5.4 ml compared with the conventional value of 106.6 ± 7.8 ml ($p = 0.001$). After 6 months no differences with respect to swelling could be documented in either group (Hilotherm 7.7 ± 3.2 ml versus conventional 5.3 ± 3.9 ml, $p = 0.6$). Maximal swelling was noted with 92.9 ± 7.0 ml during postoperative day 2 with Hilotherm and with 124.1 ± 10.1 ml during postoperative day 3 with conventional cooling.

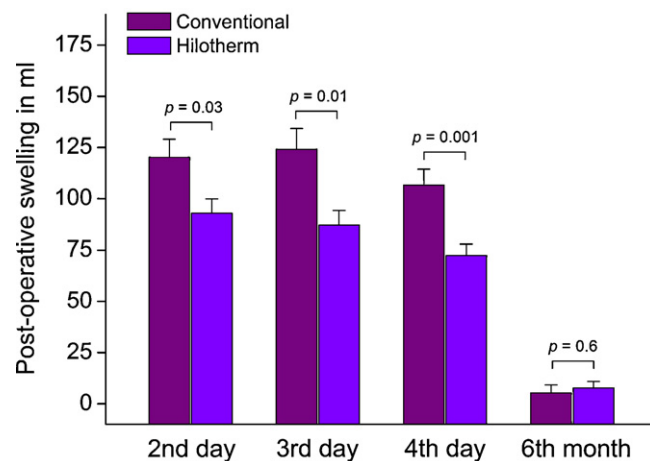


Fig. 4. The amount of swelling in ml of both groups at different time points. At postoperative day 2 a significant down-regulation of swelling could be achieved by cooling with Hilotherm compared with conventional cooling. This trend could be maintained during postoperative days 3 and 4. After 6 months no differences with respect to swelling could be documented in either group.

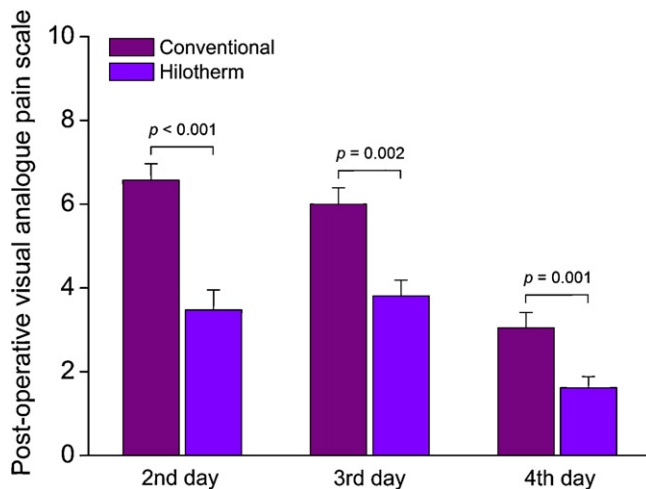


Fig. 5. Pain was calculated in terms of a VAS from subjective analysis ranging from 0 to 10. A significant increase in pain was reported in the conventional group compared with the Hilotherm group during all examined postoperative days. The pain intensity remained unchanged during the third compared with the second postoperative day in each group. A significant down-regulation of subjective pain could be achieved during the fourth compared with the second and third postoperative days in each group.

Postoperative visual analogue pain scale

Pain was subjectively assessed using a VAS ranging from 0 to 10. A significant increase of pain was reported in the conventional group compared with the Hilotherm group during all examined postoperative days (day 2: Hilotherm 3.5 ± 0.5 versus conventional 6.6 ± 0.4 , $p < 0.001$) (day 3: Hilotherm 3.8 ± 0.4 versus conventional 6.0 ± 0.4 , $p = 0.002$) (day 4: Hilotherm 1.6 ± 0.3 versus conventional 3.0 ± 0.4 , $p = 0.001$) (Fig. 5). Pain intensity remained unchanged during the third day compared with the second postoperative day in each group (Hilotherm: day 2, 3.5 ± 0.5 versus day 3, 3.8 ± 0.4 , $p = 0.586$; conventional: day 2, 6.6 ± 0.4 versus day 3, 6.0 ± 0.4 , $p = 0.309$). A significant reduction of subjective pain was achieved during the fourth compared with the second and third postoperative days in each group respectively (Hilotherm: day 2, 3.5 ± 0.5 versus day 4, 1.6 ± 0.3 , $p = 0.001$; conventional: day 2, 6.6 ± 0.4 versus day 4, 3.0 ± 0.4 , $p < 0.001$) (Hilotherm: day 3, 3.8 ± 0.4 versus day 4, 1.6 ± 0.3 , $p < 0.001$; conventional: day 3, 6.0 ± 0.4 versus day 4, 3.0 ± 0.4 , $p < 0.001$).

Postoperative neurological score

No changes were found in the Hilotherm group concerning the neurological score at day 4 and 6 months after orthognathic surgery compared with conventional cooling (day 4: Hilotherm 2.5 ± 0.3 versus conventional 2.9 ± 0.4 , $p = 0.287$) (6

months: Hilotherm 1.8 ± 0.3 versus conventional 2.0 ± 0.4 , $p = 0.54$) (Fig. 6). A highly significant decrease in neurological score was observed after 6 months compared with postoperative day 4 in each group (Hilotherm: day 4, 2.5 ± 0.3 versus 6 months 1.8 ± 0.3 , $p < 0.001$; conventional: day 4, 2.9 ± 0.4 versus 6 months 2.0 ± 0.4 , $p < 0.001$).

Mouth opening experiments

Baseline (preoperative) mouth opening values did not differ significantly between groups (Fig. 7). On postoperative day 2 there was a significant reduction in mouth opening in both groups (Hilotherm: pre-

operative 39 ± 0.5 ml versus day 2, 21.5 ± 0.6 ml, $p < 0.001$; conventional: preoperative 39 ± 0.4 ml versus day 2, 16.5 ± 0.6 ml, $p < 0.001$). The reduction in mouth opening was significantly lower in the Hilotherm group compared with the conventional group (Hilotherm 21.5 ± 0.6 ml versus conventional 16.5 ± 0.6 ml, $p < 0.001$). On postoperative day 4 a significant increase in mouth opening was achieved in both groups compared to postoperative day 2 (Hilotherm: day 2, 21.5 ± 0.6 ml versus day 4, 25 ± 0.6 ml, $p < 0.001$; conventional: day 2, 16.5 ± 0.6 ml versus day 4, 22 ± 0.5 ml, $p < 0.001$). The reduction in mouth opening remained significantly lower in the Hilotherm group compared with the conventional group on postoperative day 4 (Hilotherm 25 ± 0.6 ml versus conventional 22 ± 0.5 ml, $p < 0.001$). Six months after orthognathic surgery, mouth opening climbed to baseline (preoperative) values and no differences were observed between the groups (6 months: Hilotherm 38.6 ± 0.5 ml versus conventional 38.1 ± 0.4 ml, $p = 0.471$) and compared with baseline (Hilotherm: preoperative 39 ± 0.5 ml versus 6 months 38.6 ± 0.5 ml, $p = 0.536$; conventional: preoperative 39 ± 0.4 ml versus day 2, 38.1 ± 0.4 ml, $p = 0.163$).

Patient's satisfaction with cooling therapy

All patients were asked about their satisfaction with the postoperative cooling therapy in the form of a questionnaire. The overall satisfaction of patients in the conventional group was significantly lower compared with patients receiving

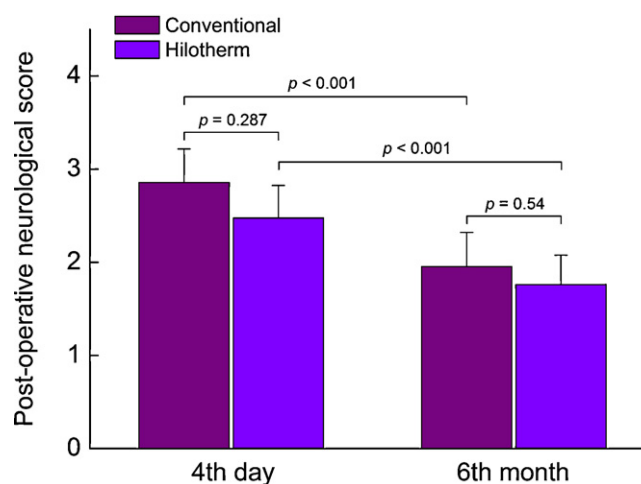


Fig. 6. No changes were found concerning the neurological score at day 4 and 6 months after orthognathic surgery in either groups. A highly significant decrease of the neurological score was observed after 6 months compared with postoperative day 4 in each group.

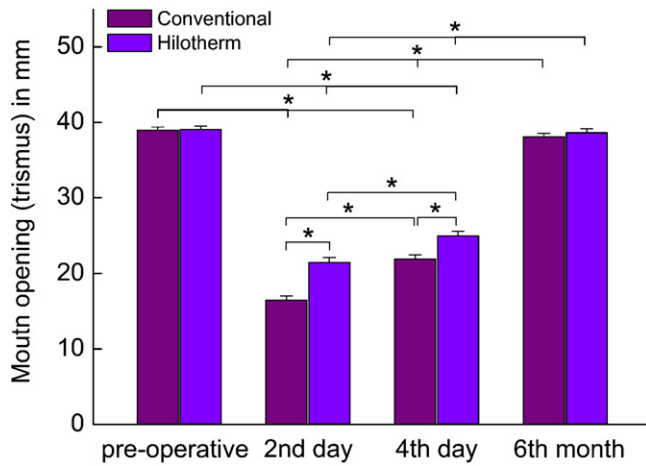


Fig. 7. Preoperative mouth opening values did not differ significantly in either group. At postoperative day 2 there was a significant reduction in mouth opening in both groups. The reduction in mouth opening was significantly lower in the Hilotherm group compared with conventional group. At postoperative day 4 a significant increase in mouth opening was achieved in both groups compared with postoperative day 2. The reduction in mouth opening remained significantly lower in the Hilotherm group compared with the conventional group at postoperative day 4. Six months after orthognathic surgery, mouth opening climbed to preoperative values and no differences were observed between groups and compared to baseline. * $p < 0.001$.

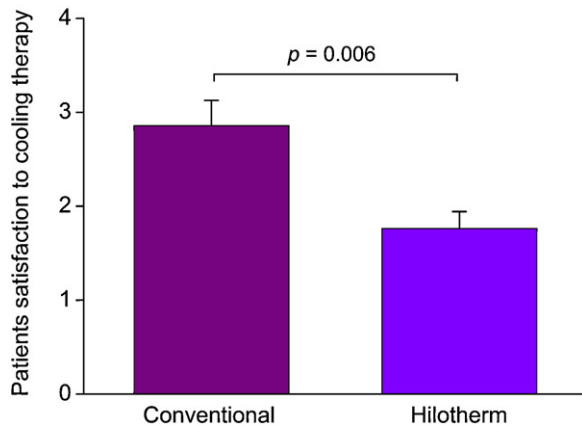


Fig. 8. Overall satisfaction was significantly lower in patients receiving conventional therapy compared with patients receiving Hilotherm cooling therapy.

the Hilotherm cooling therapy (Hilotherm 1.8 ± 0.2 versus conventional 2.9 ± 0.3 , $p = 0.006$) (Fig. 8).

Discussion

A number of different techniques have been used to measure postoperative swelling. Two well described methods are MRI and optical surface laser scanners to record and quantify facial soft tissue changes^{3,11,13,17,20}. MRI is associated with high costs, feelings of claustrophobia, the need for complex machinery and loss of time³. These disadvantages mean that it is not included in routine practice. KAU et al. demonstrated that 3D laser-scanning is a

reliable and accurate method of measuring facial swelling following surgery¹³.

In this study the authors used a new and precise method to measure face swelling after orthognathic surgery using 3D optical scanning. The system consists of an optical range sensor, two digital cameras and a mirror construction. The sensor is based on a phase-measuring triangulation method⁹. A special mirror construction was designed to allow the patient's face to be captured from ear to ear in a single recording from over 180°. The advantage of this optical sensor is contactless data acquisition along with high accuracy and short measurement time. There is no need for special safety precautions to protect

the patient from, for example ionizing radiation. The light intensity of the cameras is low. The Slim3D computer software, automatically triangulates, merges and post-processes the 3D data¹⁵. The final 3D output is a triangulated polygon mesh, visualized as a synthetically shaded or wire-mesh representation¹².

This technique was evaluated in patients undergoing orthognathic surgery in a prospective manner. Patients were divided into two groups. To reduce swelling, one group received postoperative cooling therapy with conventional methods (cold packs) and the other a cooling therapy using the water circulating cooling device from Hilotherm. Cooling by Hilotherm resulted in significantly reduced postoperative swelling compared with conventional cooling. In the Hilotherm group, maximum swelling occurred on postoperative day 2, in the conventional group it occurred on postoperative day 3. Six months after orthognathic surgery no differences were found with respect to the degree of swelling. The reduced swelling in the Hilotherm group can be explained by the precise and continuous cooling at 15 °C with the cooling mask. Cooling using cold packs results in a discontinuous and sporadically decreasing temperature. Vasoconstriction increases most at 15 °C¹⁰. When cutaneous temperature falls below 15 °C, a paradoxical vasodilatation occurs attributable to a paralysis of vascular smooth musculature or nervous conduction block of vasoconstrictive nervous fibres. This vasodilatation is a defence mechanism, to preserve blood flow at low temperature¹⁰.

Patients receiving Hilotherm cooling had a significant reduced postoperative hospital stay compared with those undergoing conventional cooling. Every reduction in hospital stay reduces the rate of nosocomial infection and reduces in-hospital morbidity and mortality.

Postoperative pain was significantly lower in the Hilotherm group compared with conventional cooling. It has been demonstrated that lowering temperature slows down peripheral nerve conduction¹. A 1 °C reduction in temperature causes 2.4 m/s reduction in peripheral nerve conduction, and at 10–15 °C, nervous conduction is abolished completely¹⁰.

Postoperative mouth opening was significantly higher in the Hilotherm group compared with the conventional cooling group. No differences were found regarding the postoperative neurological scores.

Patients receiving Hilotherm cooling therapy were more satisfied than those

receiving conventional cooling. A recent technical experience study demonstrated that HiloTherm provides a safe and effective cold therapy for controlling the post-surgery course⁴.

This measurement technique has some limitations. Volume measurement is limited to localized face swelling, because face areas that have not been affected by the swelling are necessary for surface matching. In this study, forehead, ears and the root of the nose were used for surface matching. The most limiting factor is the patient's facial expression. Different facial expressions during image acquisitions at different time points can significantly influence the volume calculations. During image acquisition, patients were instructed to maintain a neutral facial expression that felt comfortable. It is possible that volume measurements in patients with large faces can be overestimated, but this has not been investigated in the present study. There are many reasons for soft tissue swelling apart from trauma for example heart failure can cause oedema. Liver and kidney failure can be associated with soft tissue swelling, which can limit the proposed scanning technique. Diseases of vessels associated with endothelial dysfunction can induce tissue oedema, which is a further limitation of the measurement technique. Patients with such diseases should be not included for tissue swelling measurements with this technique.

In conclusion, use of the HiloTherm cooling device reduces postoperative swelling, pain and duration of hospital stay compared with conventional cooling. Postoperative mouth opening and cooling method satisfaction were increased in the HiloTherm group compared with cooling using cold packs. No differences were observed concerning the neurological score.

Competing interests

None declared.

Funding

None.

Ethical approval

Approval for the study was obtained from the relevant ethics committee at the University of Münster, Germany (CIS 2007-237-f-M). In addition, positive written consent was obtained from each subject who participated in the study.

References

1. ABRAMSON DI, CHU LS, TUCK S, LEE SW, RICHARDSON G, LEVIN M. Effect of tissue temperature and blood flow on motor nerve conduction velocity. *JAMA* 1996; **198**: 1082–1088.
2. ACKERMANN JL, PROFFIT WR, SARVER DM. The emerging soft tissue paradigm in orthodontic diagnosis and treatment planning. *Clin Orthod Res* 1999; **2**: 49–52.
3. AL-KHATEEB TH, NUSAIR Y. Effect of the proteolytic enzyme serrapeptase on swelling, pain and trismus after surgical extraction of mandibular third molars. *Int J Oral Maxillofac Surg* 2008; **37**: 264–268.
4. BELLI E, RENDINE G, MAZZONE N. Cold therapy in maxillofacial surgery. *J Craniofac Surg* 2009; **20**: 878–880.
5. CHOU SY, LIU HE. Comparison of effectiveness between moist and dry cryotherapy in reducing discomfort after orthognathic surgery. *J Clin Nurs* 2008; **17**: 1735–1741.
6. CORNELIUS CP, ROSER M, EHRENFELD M. Microneural reconstruction after iatrogenic lesions of the lingual nerve and the inferior alveolar nerve. *Critical evaluation. Mund Kiefer Gesichtschir* 1997; **1**: 213–223.
7. EPKER BN. A modified anterior maxillary osteotomy. *J Maxillofac Surg* 1977; **5**: 35–38.
8. GROSSI GB, MAIORANA C, GARRAMONE RA, BORGONOVO A, BERETTA M, FARONATO D, SANTORO F. Effect of submucosal injection of dexamethasone on postoperative discomfort after third molar surgery: a prospective study. *J Oral Maxillofac Surg* 2007; **65**: 2218–2226.
9. GRUBER M, HÄUSLER G. Simple, robust and accurate phase-measuring triangulation. *Optik* 1992; **89**: 118–122.
10. GUYTON AC. *Textbook of Medical Physiology*. 8th Edition Philadelphia, PA: WB Saunders Co 1991.
11. HAJEER MY, AYOUB AF, MILLETT DT. Three-dimensional assessment of facial soft-tissue asymmetry before and after orthognathic surgery. *Br J Oral Maxillofacial Surg* 2004; **42**: 396–404.
12. HARTMANN J, MEYER-MARCOTTY P, BENZ M, HÄUSLER G, STELLZIG-EISENHAUER A. Reliability of a Method for Computing Facial Symmetry Plane and Degree of Asymmetry Based on 3D-data. *J Orofac Orthop* 2007; **68**: 477–490.
13. KAU CH, CRONIN AJ, RICHMOND S. A three-dimensional evaluation of postoperative swelling following orthognathic surgery at 6 months. *Plast Reconstr Surg* 2007; **119**: 2192–2199.
14. KING NA, PHILPOTT SJ, LEARY A. A randomized controlled trial assessing the use of compression versus vasoconstriction in the treatment of femoral hematoma occurring after percutaneous coronary intervention. *Heart Lung* 2008; **37**: 205–210.
15. LABOUREUX X, HÄUSLER G. Localization and registration of three-dimensional objects in space – where are the limits? *Appl Optics* 2001; **40**: 5206–5216.
16. LAUREANO FILHO JR, DE OLIVEIRA E SILVA ED, BATISTA CI, GOUVEIA FM. The influence of cryotherapy on reduction of swelling, pain and trismus after third-molar extraction: a preliminary study. *J Am Dent Assoc* 2005; **136**: 774–778.
17. MEISAMI T, MUSA M, KELLER MA, COOPER R, CLOKIE CM, SÀNDOR GK. Magnetic resonance imaging assessment of airway status after orthognathic surgery. *Oral Surg Oral Med Oral Pathol Oral Radiol Endod* 2007; **103**: 458–463.
18. OBWEGESER H. The Indications for surgical correction of mandibular deformity by the sagittal splitting technique. *Br J Oral Surg* 1964; **1**: 157–171.
19. PHILLIPS C, BLAKEY 3rd G, JASKOLKA M. Recovery after orthognathic surgery: short-term health-related quality of life outcomes. *J Oral Maxillofac Surg* 2008; **66**: 2110–2115.
20. RØYNESDAL AK, BJÖRNLAND T, BARKVOLL P, HAANAES HR. The effect of soft-laser application on postoperative pain and swelling. A double-blind, crossover study. *Int J Oral Maxillofac Surg* 1993; **22**: 242–245.
21. SCHAUBEL HJ. The local use of ice after orthopaedic procedures. *Am J Surg* 1946; **72**: 711–714.
22. SZOLNOKY G, SZENDI-HORVÁTH K, SERES L, BODA K, KEMÉNY L. Manual lymph drainage efficiently reduces postoperative facial swelling and discomfort after removal of impacted third molars. *Lymphology* 2007; **40**: 138–142.
23. TUZUNER AM, UCOK C, KUCUKYAVUZ Z, ALKIN N, ALANOGLU Z. Preoperative diclofenac sodium and tramadol for pain relief after bimaxillary osteotomy. *J Oral Maxillofac Surg* 2007; **65**: 2453–2458.
24. VAN DER WESTHUIJZEN AJ, BECKER PJ, MORKEL J, ROELSE JA. A randomized observer blind comparison of bilateral facial ice pack therapy with no ice therapy following third molar surgery. *Int J Oral Maxillofac Surg* 2005; **34**: 281–286.

Address
 Dr. Majeed Rana
 Department for Oral and Maxillofacial
 Surgery
 Hannover Medical School
 Carl-Neuberg-Str. 1
 D-30625 Hannover
 Germany
 Tel: +49 511 532 4748
 Fax: +49 511 532 4740
 E-mail: rana.majeed@mh-hannover.de